

The effects of functional magnetic stimulation (FMS) on the rectus abdominis muscle size and abdominal subcutaneous adipose tissue thickness

Roberto Valdivia¹

¹ Medicina Estética y Antienvjecimiento, Escazú, Costa Rica

ABSTRACT

Objective The aim of this prospective study was to investigate safety and efficiency of using functional magnetic stimulation technology for abdominal muscle toning, shaping, and strengthening.

Methods Ten participants (4 men, 6 women) received 10 sessions of repetitive magnetic stimulation, using the Tesla Former prestige device. Efficacy was evaluated through waist circumference, MRI imaging and patient satisfaction.

Results On the 10-week follow-up we observed a waist circumference reduction of -2.76 ± 1.37 cm, as compared to the baseline. On the patients that have undergone MRI imaging, the *rectus abdominalis* muscles thickness was increased by 5.98 ± 1.87 mm and subcutaneous abdominal fat thickness was decreased by -4.35 ± 2.80 mm.

Conclusion FMS magnetic stimulation seems to be an effective and safe method for muscle toning and body shaping, resulting in an increase in muscle mass in the treated area as well as a decrease in subcutaneous fat, resulting with visible improvement in abdominal body shape and very high patient satisfaction rates.

INTRODUCTION

Pulsed magnetic stimulation using high intensity magnetic fields has been introduced in the 1980's by Barker and colleagues¹ and has firstly been recognized as a tool for diagnostic and therapeutic nerve stimulation and muscle contraction. Recently, it is becoming increasingly popular as a non-invasive method for muscle strengthening and body shaping.

High intensity magnetic stimulation works by inducing currents in the biological tissue, leading to nerve stimulation. The induced action potentials in the efferent nerves results with a contraction of the targeted muscles². Magnetic stimulation is especially suitable for this sort of application, as the magnetic field is able to easily penetrate through skin and can also affect deeper lying nerves and muscles.

Traditionally, transcutaneous electrical stimulation has been used to induce nerve stimulation and muscle contraction, although its limitations are low penetration and pain at stimulation intensity levels needed for efficient muscle contraction. The magnetic field is able to propagate deep inside the tissue without stimulating the pain receptors in the upper layers of the skin; therefore the treatment is not painful and can be easily tolerated at higher intensities³. Due to this advantage, the popularity of magnetic stimulation in the field of muscle toning is rising as opposed to electrical stimulation.

Recent studies have shown that treatment of abdominal muscles using high intensity magnetic muscle stimulation resulted in increased muscle size and strength additionally it even decreased the subcutaneous fat layer^{4,5}.

The aim of this prospective study was to investigate safety and efficiency of using functional magnetic stimulation technology for abdominal muscle toning, shaping and strengthening. We also aimed to investigate whether the intensive muscle contractions result in changes of the subcutaneous fat and abdominal muscle thickness.

METHODS

10 participants (4 men, 6 women) took part in the clinical study, with an average age of 32.7 years old.

The study was done according to the Declaration of Helsinki, including healthy volunteers, all of whom signed the informed consent form.

Abdominal muscle stimulation treatment

All patients received 10 sessions of repetitive magnetic stimulation, using the Tesla Former prestige device (Iskra Medical, Slovenia). The treatments were performed using two large FMS applicators that have been connected together side by side and attached to the abdomen using the fixing straps. The intensity of the treatments can vary between 2 and 100% of the total device magnetic field intensity of 3 T. The intensity was set to fit the individual tolerability level of each participant. The treatment was 30 minutes long, with several steps including different frequency modulations in order to achieve stimulation of different muscle fibers. The preset program called Abdomen 2 was used for the stimulation. 10 sessions were performed altogether, with 2 days in between each session. Potential adverse events during or after the treatment were monitored in all patients.

Evaluation methodology

All participants were weighed at baseline and at each follow-up to check for changes in body

weight that could affect the final visual result. Waist circumference was measured at baseline and at follow-ups 10 weeks after the last treatment session. Waist circumference was measured at the level of anterior superior iliac spine (ASIC) as well as 3 cm above ASIC and 3 cm below ASIC.

Patient satisfaction was recorded using an original questionnaire, which included questions about the satisfaction with muscle appearance, strength and the perceived muscle contraction strength during muscle stimulation, which was evaluated on a 1-5 scale (1 = none; 2 = low; 3 = moderate, 4 = high, 5 = very high). The patients were also asked about the willingness to repeat and recommend the treatment to others. three randomly chosen patients that have been included in the study have also undergone magnetic resonance imaging (MRI) to determine the extent of any potential changes in the muscle and/or the subcutaneous fat layer thickness. The image acquiring and the analysis of cross-sectional MRI images was performed by an expert radiologist.

Statistical evaluation

Anonymized data was entered into an Excel spreadsheet. Descriptive and comparative statistics were analyzed using standard spreadsheet software (Microsoft Excel, USA).

RESULTS

The responses from the patient questionnaire indicated high patient satisfaction. The patient's perceived improvement in abdominal body shape was 4.3 on a 1-5 scale (Table 1). The average weight change from baseline to the 10-week follow-up was -0.6 ± 1.35 kg and which is clinically irrelevant. There was a significant decrease ($p < 0.001$) in waist circumference of -2.76 ± 1.37 cm, as compared to the baseline.

The results from cross-sectional MRI analysis show an increase in thickness of rectus abdominis muscle of $40.6 \pm 17.5\%$; and a decrease

in subcutaneous fat layer above the rectus abdominis muscle of $25.9 \pm 5.7\%$ (Figure 1).

There were no reported adverse events during or after the therapy.

Table 1 – The results of the patient questionnaire for each patient.

Patient No.	Sex	Patient's perceived muscle contraction intensity during treatment (1-5 scale)	Patient's perceived improvement in muscular strength (1-5 scale)	Patient satisfaction with body shape (1-5 scale)
1	F	4	3	4
2	F	4	5	5
3	M	5	4	4
4	M	5	5	5
5	M	3	3	4
6	F	3	3	3
7	F	4	5	4
8	M	5	5	5
9	F	4	4	5
10	F	4	4	4
average		4.1	4.1	4.3
SD		0.73	0.87	0.67

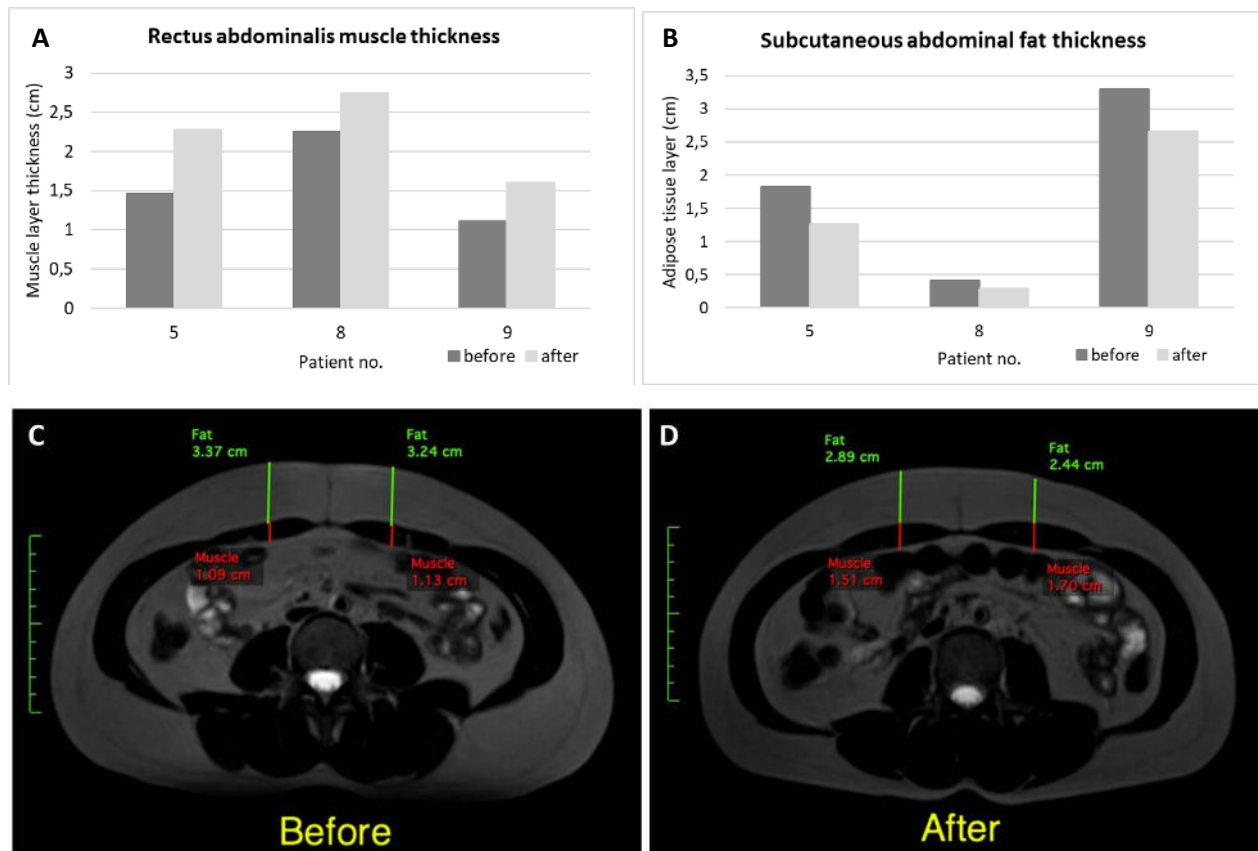


Figure 1. A - Measured change in rectus abdominis muscle thickness before and 10 weeks after the FMS treatment, taken from MRI transverse abdominal sections from 3 patients; **B** Measured change in abdominal subcutaneous fat muscle thickness before and 10 weeks after the FMS treatment, taken from MRI transverse abdominal sections from 3 patients; **C and D** – example of an MRI image of patient No. 9 taken before (A) and 10 weeks after (D) FMS treatment

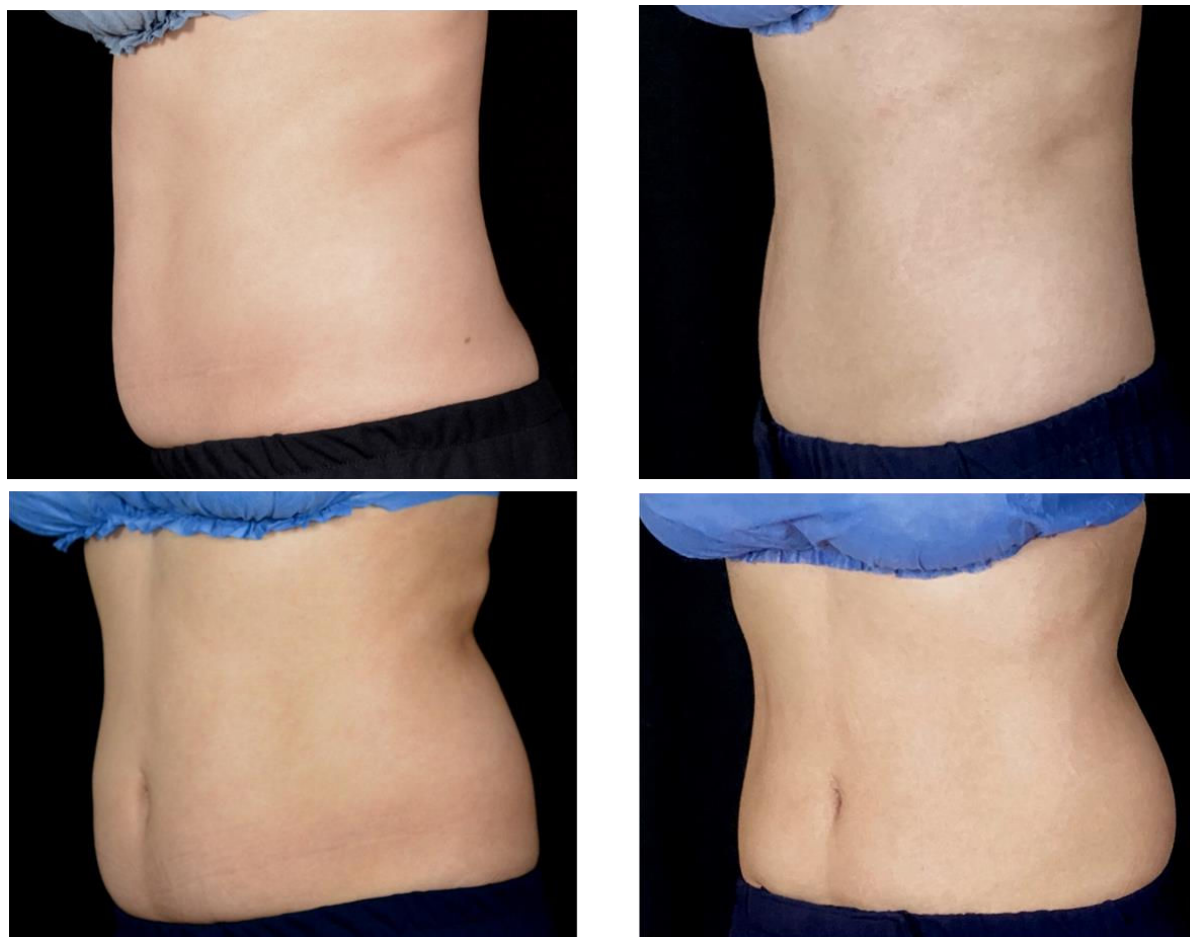


Figure 2 Before (left) and after (right) photograph of patient No. 9 (see Figure 1C and 1D for an MRI image from the same patient) with evident abdominal body shape aesthetic improvement.

DISCUSSION

Our study has shown that magnetic stimulation is an effective treatment for abdominal muscle toning and body shaping. Analysis of MRI images revealed an increase in abdominal muscle thickness and a decrease in subcutaneous fat 2.5 months following magnetic stimulation treatment. There was a significant decrease in waist circumference (up to 3cm on average), which was not connected to weight fluctuations, as the patient's weight did not significantly change. Visual improvement in abdominal muscle toning and body shape, as determined by

the patient satisfaction questionnaire, was evident in all treated patients. The patients were very satisfied with visual as well as functional (perceived muscle strength) improvement, which was measured 10 weeks after the last treatment session.

The intensity of the magnetic field in the device used in this study was high enough to induce the current in the underlying neurons and cause muscle contraction. Muscle hypertrophy is most optimally achieved when repeated contractions of above 60% maximum voluntary contraction (MVC) are elicited in resistance training⁶. Since high intensity magnetic

stimulation is painless, it can be used at higher intensities, enabling stronger muscle contractions than when electrical stimulation is used. For example in a study by Kremenec et al.⁷, an average MVC of 72% was elicited by magnetic stimulation of the quadriceps femoris muscle. A study using electrical stimulation of the same muscle has reported much lower achieved MVC values, which were limited by the discomfort felt by the patient when increasing the current intensity⁸. In this study we did not measure MVC values but have asked the patients to assess the strength of perceived muscle contraction. They have rated the strength of abdominal muscle contraction as 4.1 on a 1-5 scale, indicating a high achieved MVC value, which was evident also from the observed visual changes and improvement in perceived muscular strength. By using a range of frequencies during the treatment protocol, both slow- and fast- twitch muscle fibers are activated, resulting with uniform muscle contraction of all motor units, some of which would normally require high-intensity exercise to be activated⁹. Alon et al.¹⁰ have compared differences in muscle strength in 3 groups – i) exercise alone; ii) electrical stimulation alone; or iii) combination of exercise and electrical stimulation. They have shown that electrical stimulation in combination with exercise produced the highest increase in isometric muscle strength, while electrical stimulation alone produced better results than exercise alone. Magnetic stimulation shares some of the mechanism of action as electrical muscle stimulation, without the downsides of applying transcutaneous electrical currents which can cause pain. As the magnetic stimulation is able to reach deep muscles structures this method could be an excellent complementary muscle shaping method in addition with exercise; as well as an excellent option to increase muscle strength in less active individuals.

The increase in muscle thickness of rectus abdominis muscle of $40.6 \pm 17.5\%$ was evident from the analysis of cross-sectional MRI images taken from 3 patients at baseline and at 3 months follow-up. At the same time, an overall

decrease in subcutaneous fat was observed from the cross-sectional MRI image, as well as from the measurements of subcutaneous fat layer thickness above the rectus abdominis muscle, which showed a decrease of $5.9 \pm 5.7\%$. This is consistent with the results of previous studies that used magnetic muscle stimulation. These results corroborate previously published data using similar technologies^{4,5,11}.

In two studies by Kinney et al.^{4,11} muscle thickness evaluation after abdominal magnetic stimulation was performed using MRI⁴, with follow up of 12 months¹¹. Analysis of MRI slices showed significant average increase in muscle thickness of 19.05% (1.89 ± 0.88 mm) and reduction in fat of 14.63% (2.97 ± 2.11 mm).

Decrease in fat layer thickness following magnetic stimulation was also measured in two studies using ultrasound evaluation, which have shown a similar pattern of significant increase in muscle thickness and decrease in subcutaneous fat layer post abdominal magnetic stimulation^{12,13}. Since a human histological study¹⁴ found no fat cell injury or inflammatory response 3–17 days following a single session of magnetic muscle stimulation, it can be speculated that the fat layer may be reduced by increased catabolic fat metabolism due to contraction of large muscles following magnetic stimulation or due to synergistic changes in diet and/or physical activity, which cannot be observed histologically. The limitations of this study are a small study population, lack of a control group and a short follow-up period. The optimal treatment number and maintenance schedule still needs to be determined and should be the subject of further clinical research.

CONCLUSIONS

FMS magnetic stimulation seems to be an effective and safe method for muscle toning and body shaping, resulting in an increase in muscle mass in the treated area as well as a decrease in subcutaneous fat, resulting with visible improvement in abdominal body shape and very high patient satisfaction rates.

REFERENCES

1. Barker, A. T., Freeston, I. L., Jalinous, R. & Jarratt, J. A. Magnetic stimulation of the human brain and peripheral nervous system: an introduction and the results of an initial clinical evaluation. *Neurosurgery* 20, 100–109 (1987).
2. Machetanz, J. *et al.* Magnetically induced muscle contraction is caused by motor nerve stimulation and not by direct muscle activation. *Muscle Nerve Off. J. Am. Assoc. Electrodiagn. Med.* 17, 1170–1175 (1994).
3. Beaulieu, L.-D. & Schneider, C. Repetitive peripheral magnetic stimulation to reduce pain or improve sensorimotor impairments: a literature review on parameters of application and afferents recruitment. *Neurophysiol. Clin. Neurophysiol.* 45, 223–237 (2015).
4. Kinney, B. M. & Lozanova, P. High intensity focused electromagnetic therapy evaluated by magnetic resonance imaging: Safety and efficacy study of a dual tissue effect based non-invasive abdominal body shaping. *Lasers Surg. Med.* 51, 40–46 (2019).
5. Jacob, C. *et al.* High intensity focused electromagnetic technology (HIFEM) for non-invasive buttock lifting and toning of gluteal muscles: a multi-center efficacy and safety study. *J. drugs dermatology JDD* 17, 1229–1232 (2018).
6. Garber, C. E. *et al.* Quantity and quality of exercise for developing and maintaining cardiorespiratory, musculoskeletal, and neuromotor fitness in apparently healthy adults: guidance for prescribing exercise. (2011).
7. Kremenich, I. J., Ben-Avi, S. S., Leonhardt, D. & McHugh, M. P. Transcutaneous magnetic stimulation of the quadriceps via the femoral nerve. *Muscle Nerve Off. J. Am. Assoc. Electrodiagn. Med.* 30, 379–381 (2004).
8. Laufer, Y., Ries, J. D., Leininger, P. M. & Alon, G. Quadriceps femoris muscle torques and fatigue generated by neuromuscular electrical stimulation with three different waveforms. *Phys. Ther.* 81, 1307–1316 (2001).
9. Gregory, C. M. & Bickel, C. S. Recruitment Patterns in Human Skeletal Muscle During Electrical Stimulation. *Phys. Ther.* 85, 358–364 (2005).
10. Alon, G. *et al.* Comparison of the effects of electrical stimulation and exercise on abdominal musculature. *J. Orthop. Sport. Phys. Ther.* 8, 567–573 (1987).
11. Kinney, B. M. & Kent, D. E. MRI and CT Assessment of Abdominal Tissue Composition in Patients After High-Intensity Focused Electromagnetic Therapy Treatments: One-Year Follow-Up. *Aesthetic Surg. J.* 40, NP686–NP693 (2020).
12. Giesse, S. A German Prospective Study of the Safety and Efficacy of a Non-Invasive, High-intensity, Electromagnetic Abdomen and Buttock Contouring Device. *J. Clin. Aesthet. Dermatol.* 14, 30 (2021).
13. Katz, B., Bard, R., Goldfarb, R., Shiloh, A. & Kenolova, D. Ultrasound assessment of subcutaneous abdominal fat thickness after treatments with a high-intensity focused electromagnetic field device: a multicenter study. *Dermatologic Surg.* 45, 1542–1548 (2019).
14. Zachary, C. B., Burns, A. J., Pham, L. D. & Jimenez Lozano, J. N. Clinical Study Demonstrates that Electromagnetic Muscle Stimulation Does Not Cause Injury to Fat Cells. *Lasers Surg. Med.* 53, 70–78 (2021).